Hoffmann F[1], Heinz L[1], Mouton C[1,2], Seil R[1,2,3], Nührenbörger C[1,2]

Unusual Cause of Lumbar Pain in Elite Sports: Two Case Reports of Sacral Stress Fractures

Ungewöhnliche Ursache für lumbale Beschwerden im Leistungssport: Fallbeispiele von Stressfrakturen des Sakrums

CASE REPORT

ACCEPTED: December 2021

PUBLISHED ONLINE: February 2022

Hoffmann F, Heinz L, Mouton C, Seil R, Nührenbörger C. Unusual cause of lumbar pain in elite sports: 2 case reports of sacral stress fractures. 2022; 73: 43-48. doi:10.5960/dzsm.2021.515

1. CENTRE HOSPITALIER DE LUXEMBOURG, *Sports Clinic, Luxembourg, Luxembourg*
2. LUXEMBOURG INSTITUTE OF RESEARCH IN ORTHOPAEDICS, SPORTS MEDICINE AND SCIENCE, *Luxembourg, Luxembourg*
3. LUXEMBOURG INSTITUTE OF HEALTH, *Human Motion, Orthopaedics, Sports Medicine and Digital Methods, Luxembourg, Luxembourg*

Summary

- **Nonspecific lower back and buttock pain** can significantly limit performance in athletes and can be of different origins. Sacral stress fractures are a rare and, in many cases, undiagnosed cause of lower back pain, which can lead to a substantial loss of time before a full return-to-sports is achieved with full athletic performance.
- **The main risk factors** of sacral stress fractures include repetitive full weight-bearing activities, short-term increases in exercise intensity or duration, and excessive energy deficit. Knowledge of the injury pattern, high clinical suspicion, and early MRI examination lead to a timely diagnosis. Therapeutically, load reduction with avoidance of high impact activities for at least 6 weeks is indicated initially, followed by dosed and progressive load increase. In parallel, supplementation with calcium and vitamin D is recommended. Athletes with recurrent stress fractures, regardless of region, should be evaluated for a "Female Athlete Triad" or its male counterpart, as well as endocrinologic risk factors. Preventive measures are possible for stress fractures but are not specific to sacral stress fractures.
- **We describe two clinical case scenarios**, one of a professional soccer player and one of an elite track and field athlete with sacral stress fractures as the cause of nonspecific lumbar pain.

KEY WORDS:
Lower Back Pain, Sacrum, Football, Middle Distance Running

Zusammenfassung

- **Unspezifische Beschwerden des Lendenwirbel- und Gesäßbereiches** können bei Sportlern die Leistungsfähigkeit erheblich einschränken und unterschiedlichen Ursprungs sein. Die sakrale Stressfraktur stellt eine seltene und in vielen Fällen nicht diagnostizierte Ursache von Kreuzschmerzen dar, wobei es zu einem erheblichen Zeitverlust kommen kann, bis die volle Sportfähigkeit wiederhergestellt ist.
- **Zu den Hauptrisikofaktoren** sakraler Stressfrakturen zählen repetitive Aktivitäten in Vollbelastung, eine kurzfristige Steigerung der Trainingsintensität oder -dauer, sowie ein zu hohes Energiedefizit. Das Wissen über das Verletzungsbild, ein hoher klinischer Verdacht sowie die frühzeitige MRT-Untersuchung führen zu einer zeitnahen Diagnose. Therapeutisch ist zunächst eine Belastungsreduktion mit Vermeidung von Aktivitäten mit hohem Impakt für mindestens sechs Wochen indiziert, mit anschließender dosierter und progressiver Belastungssteigerung. Parallel hierzu wird eine Supplementation mit Kalzium und Vitamin D empfohlen. Bei Sportlern mit rezidivierenden Stressfrakturen, unabhängig von der Region, sollten Untersuchungen bezüglich einer „Female Athlete Triad" oder dessen männlichen Pendants, sowie die Abklärung endokrinologischer Risikofaktoren erfolgen. Präventive Maßnahmen finden sich bislang nur allgemein zu Stressfrakturen.
- **Wir beschreiben zwei klinische Fälle**, einen aus dem professionellen Fußball und einen aus der Leichtathletik, mit sakralen Stressfrakturen als Ursache unspezifischer lumbaler Beschwerden.

SCHLÜSSELWÖRTER:
Lumbalgie, Sakrum, Fußball, Mittelstreckenlauf

Scan QR Code and read article online.

CORRESPONDING ADDRESS:
Felix Hoffmann, Specialist in orthopedics and trauma surgery
Clinique du Sport, CHL Eich, 76, rue d'Eich, L-1460 Luxembourg
: hoffmann.felix@chl.lu

Introduction

Atraumatic fractures can be divided into pathologic, insufficiency, and stress fractures. Insufficiency fractures usually occur during physiological loading on osteopenic or osteoporotic bone, whereas stress fractures occur during non-physiologically high or highly repetitive loading on healthy bone. For this reason, insufficiency fractures are more common in older patients while stress fractures are typically overuse injuries observed in athletes (12, 20). A distinction can be made between "high-risk" and "low-risk" stress fractures. Sacral stress fractures belong to the latter due to their good healing potential (10).

Sacral stress fractures are rare and were first described by Volpin in 1989 (19). Their diagnosis is often delayed or overlooked because of the nonspecific lumbar pain which may lead to a preferential ›

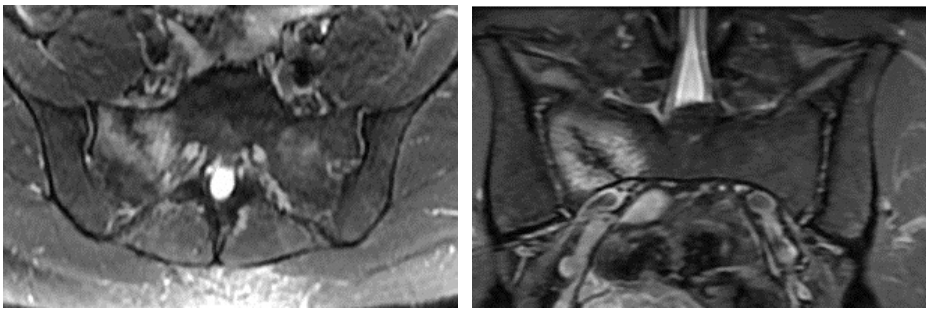

Figure 1

Initial pelvic MRI (a: DP T2 FS axial, b: coronal) showing edema and a right sacral stress fracture (case 1).

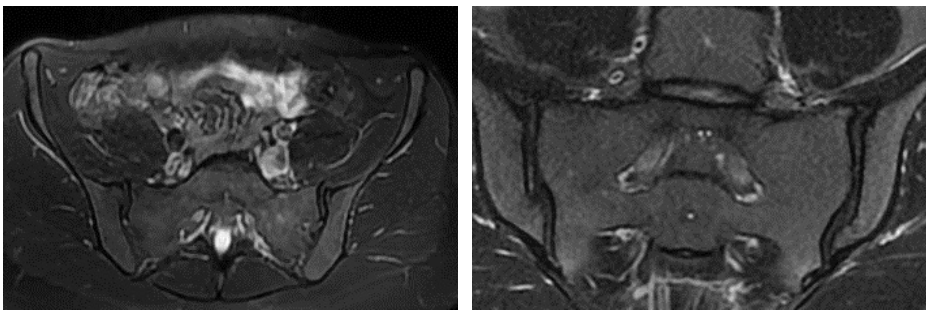

Figure 2

Pelvic MRI (a: DP T2 FS axial, b: coronal) 5 months after diagnosis with consolidation of the fracture and resolution of the bone edema in the right sacrum (case 1).

consideration of other diagnoses (4). The classification used for sacral stress fractures is the same as for acute traumatic sacral fractures and is based on the anatomical course of the fracture line in relation to the neural foramina (3). Type I fractures run lateral to the foramina, type II fractures run transforaminal and type III fractures run medial to the foramina. The classification allows prognostic conclusions to be drawn regarding the frequency of neurological concomitant injuries, which increase from lateral to medial.

The aim of the present report is to describe two clinical case scenarios, one of a professional soccer player and one of an elite track and field athlete with sacral stress fractures as the cause of nonspecific lumbar pain.

Case 1

The first case concerns a 26-year-old female elite middle-distance runner who had been complaining of recurrent pain in the lumbar spine and in the posterior pelvic region for 3 months. Before the onset of symptoms, she was preparing for a competition with 16 hours of practice on 7 days per week, running up to 120km. As a first self-administered treatment, the patient did short breaks of 8 to 10 days, as well as load reductions which did only lead to a temporary pain relief. At the first medical visit, the training load was significantly reduced and limited to swimming.

The patient's medical history included overuse-related complaints of the patellar tendon and the iliotibial tract. The athlete had a BMI of 20.1 kg/m^2. During clinical examination, there was a moderate local tenderness over the facets of the lower lumbar spine and sacroiliac joints, as well as over the symphysis and adjacent pubic bones. The rest of the clinical examination did not reveal any abnormality.

Initial radiographs of the pelvis and hip did not show any structural abnormality. Magnetic resonance imaging (MRI) of the pelvis showed signs of minor symphysitis and, most importantly, a clear type I stress fracture and edema of the right lateral massa of the left Os sacrum (Figure 1).

The patient reported no symptoms of the "female athlete's triad" (amenorrhea, eating disorder and osteoporosis). The laboratory parameters of inflammation and bone metabolism values for calcium, parathormone and vitamin D were within the normal range.

Therapeutically, the patient initially underwent a 3-week full rest without any exercise being allowed, followed by a clinical check-up and then a progressive increase in exercise with alternative sports (swimming, cycling). In addition, the patient was supplemented with 1mg of Calcium and 8 U.I with vitamin D per day, until full return to sports. Six weeks after diagnosis, a follow-up MRI confirmed the complete reduction of the edema at the sacrum. The stress fracture was however still visible and not completely healed. As the patient did not complain anymore about pain in the sacrum or the lumbar spine, pelvic stabilizing exercises and running with 30% of the body weight on an anti-gravity treadmill were allowed and increased to 50% in a progressive manner.

Three months after the diagnosis, the patient was symptom-free while running with 50% of the body weight on the anti-gravity treadmill and the clinical examination did not reveal any abnormality. It was thus decided to allow running to 100% of the body weight. After 5 months, the athlete was able to fully return to sports and competition without any sacral discomfort. Follow-up MRI showed no further sacral fracture (Figure 2).

Case 2

The second case concerns a 23-year-old professional left-footed soccer player who had to stop training due to severe low back pain. The complaints had started with pain in the lower back after a 10 km run during the winter break, which then progressively increased within two weeks. The patient's history showed no relevant previous injuries and no previous experience of lumbar pain. The weekly training load before the onset of complaints consisted of six hours of football practice, 6-8 hours of strength training and another 4-6 hours of endurance training.

Clinically, there was limited mobility of the lumbar spine and hip joints with poor neuromuscular control of the pelvis and a nonspecific and diffuse pain at pressure over the lower lumbar back, particularly in the area of the left sacroiliac joint and sacrum. Testing of the lumbar spine with the Stork's test was normal. Radiographs revealed a L5 spondylolysis with a first-degree spondylolisthesis of L5/S1.

Physical therapy and local intramuscular infiltration with local anesthetic were prescribed but only helped brief-

ly so that an MRI was prescribed. The latter confirmed the diagnosis of a Denis type I sacral stress fracture of the left massa lateralis (Figure 3).

Initially, a 6-week rest was requested and a supplementation with 1mg of calcium and 800 U.I. of vitamin D was started until full return to sports. The club physician added an additional treatment with 200mcg of vitamin K per day. Then, progressive loading was authorized and organized in collaboration with the patient's physiotherapist and athletic trainer. The goal was to allow for a decompression of the fracture while losing as little endurance and strength as possible, especially in the upper body and trunk. Relaxing and stretching measures were thus used, as well as neuromuscular exercises for pelvic stability. Swimming and whole-body training without unilateral loads were also allowed. In addition, calcium and vitamin D substitutions were initiated.

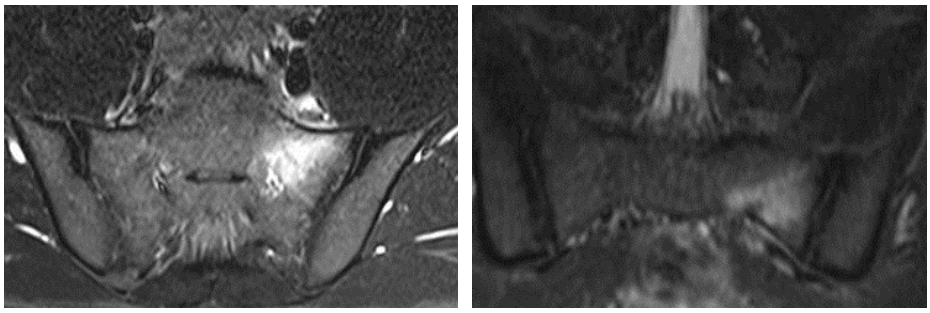

Figure 3

Initial pelvic MRI (a: T2 TIRM axial, b: T2 P2 coronal) showing bone edema and a left sacral stress fracture (case 2).

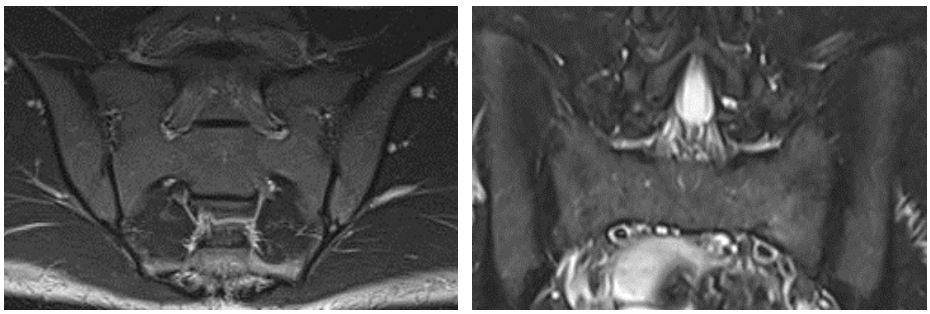

Figure 4

Pelvic MRT (a: T2 TIRM axial, b: coronal) 3,5 months after diagnosis with almost complete consolidation of the sacral stress fracture (case 2).

Six weeks after the diagnosis, the follow-up MRI already showed a significant reduction of the bone edema as well as early signs of fracture healing. Running for a maximum of 30 minutes with 20% of the body weight on an anti-gravity treadmill was therefore started. This load was increased weekly by 10% if the patient was symptom-free. A last MRI 10 weeks after diagnosis only showed discrete bone marrow edema and minimal fracture residuals (Figure 4) so that the athlete was allowed to jog slowly with full weight-bearing. Overall, return to team practice occurred after 108 days and a return to competitive sports after an additional 10 days with a total absence of 17 league games.

Discussion

Non-specific lumbar complaints are common in the general population as well as among athletes. In the two reported clinical case scenarios, they were caused by a sacral stress fracture in two elite level athletes. These are often underdiagnosed, because symptoms mimic other pathologies, including spondylolisthesis, degenerative discopathy, facet joint arthropathy, spinal compression fracture, iliosacral dysfunction, and also muscle strains of the lower back (14, 21). The incidence of overuse-related stress fractures is generally estimated at 2 to 4 % in athletes (9, 16). In professional soccer, they only represent 0.5 % of all injuries, with the fifth metatarsal being affected the most (5). In runners, the incidence of stress fractures is thought to be as high as 20 % (2). However, no accurate data on the incidence of sacral stress fractures are available since they are rare and, in most cases, undiagnosed (20).

Sacral stress fractures are common in athletes aged 20 to 40 years (14, 20). The main risk factors include long-distance running, repetitive activities in full load for a long time, short-term increases in training intensity or duration, and inadequate nutrition or excessive energy deficit (4, 7). Stress fractures of the femur, pelvis, and sacrum are more common in female athletes (8, 13) due to low estrogen levels affecting the density of cancellous bone (6). In females with recurrent fractures, one should thus not forget to evaluate the "female athlete's triad": eating disorder, amenorrhea for more than 3 cycles, osteoporosis with a T-score of > -2.5 on bone densitometry (6). An analogous process can be observed in male athletes and include energy deficit (with or without eating disorder), hypogonadotropic hypogonadism, and reduced bone density (17).

In the second case, there was an incidental finding of a spondylolysis of L5 with a first-degree spondylolisthesis of L5/S1. To our knowledge, a correlation between the presence of a spondylolisthesis and the presence of a sacral stress fracture has not been previously reported in the literature. Only one case report with sacral insufficiency fracture, advanced spondylolisthesis, severely degenerative disc and concomitant osteoporosis could be identified. In this case, the fracture line was vertical, so the insufficiency fracture was probably due to direct force transmission to the ventral edge of the sacrum (15). The question to which extent the spondylolysis has contributed to triggering the sacral stress fracture, thus remains open.

In contrast to osteoporotic insufficiency fractures in elderly patients, which can also occur bilaterally, only unilateral sacral stress fractures have been described in athletes (18). A correlation regarding dominant leg or direction of running during lap running on the track is not known. As a biomechanical factor of local overload, leg length discrepancy may contribute to the development of sacral stress fractures (17). Other biomechanical factors such as hyperlordosis or muscular imbalances and weaknesses have not been listed as causative factors in sacral stress fractures. The limited mobility of the lumbar spine and hip joints with ›

poor neuromuscular control of the pelvis in case 2 may have resulted in unilateral overload in the left-footed patient and may be a contributing cause of his left sacral stress fracture.

Clinically, pain is usually reported in the lower back as well as the buttocks for sacral stress fractures and worsens with exercise. In some cases, pain in the hip region or groin can however also be described. On physical examination, localized tenderness is found over the sacrum as well as the sacroiliac joint.

Sacral stress fractures are often not adequately visualized with standard radiographs, which are usually requested at the initial visit. Bone scans (scintigraphy), computed tomography (CT), or MRI are necessary, with MRI being the diagnostic modality of choice (7, 12, 21). Sacral stress fractures are almost exclusively located in Denis zone I, as they were in both of the reported cases. They show a vertical course, running parallel to the sacroiliac joint, thus suggesting a direct relationship with suspected weight transmission through the spine. Neurological symptoms with sensorimotor deficits have not been described (20). Transverse fractures, on the other hand, are excessively rare (11).

Initially, load reduction with avoidance of high-impact activities for at least 6 weeks is indicated, with subsequent progressive loading (18). Especially for running, this can be controlled with the use of an anti-gravity treadmill, as it allows normal running while reducing the impact on the bony skeleton. MRI can be used for load control and can be helpful in determining when to resume specific sports activities (return-to-sports). In parallel, supplementation with calcium and vitamin D is recommended. In case of persistent vitamin D deficiency despite supplementation with vitamin D, further endocrinological evaluation should be performed. Other therapeutic measures with low-energy pulsed ultrasound and electric field stimulation as used for other stress fractures were not reported for sacral stress fractures in the literature (1). No surgical therapy was described.

Preventive measures are possible for stress fractures but are not specific to sacral stress fractures (1). They include recognition of rapid growth phases in adolescent athletes, adaptation of training loads, dietary measures for energy deficiencies, vitamin D and calcium supplementation for deficiencies, and biomechanical screening. Good sport-specific muscular balance, joint mobility and neuromuscular control is important to avoid imbalance or overloads. They should therefore not only be corrected when complaints arise, but should already be addressed preventively.

Conclusion

Sacral stress fractures are a rare cause of overuse-related complaints of the lower back and buttocks. Especially in performance-oriented athletes and the presence of typical risk factors such as long-distance running, short-term increase in training intensity and inadequate nutrition, sacral stress fractures should be considered and imaging by MRI should be performed early.

Therapeutically, the primary treatment for this "low-risk" stress fracture is conservative treatment with load reduction over several weeks. Other risk factors such as the "female athlete's triad" or its male counterpart should be excluded or treated, especially in the case of multiple stress fractures.

Conflict of Interest
The authors have no conflict of interest.

References

(1) **BECK B, DRYSDALE L.** Risk Factors, Diagnosis and Management of Bone Stress Injuries in Adolescent Athletes: A Narrative Review. Sports (Basel). 2021; 9: 52. doi:10.3390/sports9040052

(2) **BODEN BP, OSBAHR DC.** High-risk stress fractures: evaluation and treatment. J Am Acad Orthop Surg. 2000; 8: 344-353. doi:10.5435/00124635-200011000-00002

(3) **DENIS F, DAVIS S, COMFORT T.** Sacral fractures: an important problem. Retrospective analysis of 236 cases. Clin Orthop Relat Res. 1988; 227: 67-81.

(4) **DUTTON RA.** Stress Fractures of the Hip and Pelvis. Clin Sports Med. 2021; 40: 363-374. doi:10.1016/j.csm.2020.11.007

(5) **EKSTRAND J, TORSTVEIT MK.** Stress fractures in elite male football players. Scand J Med Sci Sports. 2012; 22: 341-346. doi:10.1111/j.1600-0838.2010.01171.x

(6) **FEINGOLD D, HAME SL.** Female athlete triad and stress fractures. Orthop Clin North Am. 2006; 37: 575-583. doi:10.1016/j.ocl.2006.09.005

(7) **FICEK K, CYGANIK P, RAJCA J, RACUT A, KIEŁTYKA A, GRZYWOCZ J, HAJDUK G.** Stress fractures in uncommon location: Six case reports and review of the literature. World J Clin Cases. 2020; 8: 4135-4150. doi:10.12998/wjcc.v8.i18.4135

(8) **JOHNSON AW, WEISS CB JR, STENTO K, WHEELER DL.** Stress fractures of the sacrum. An atypical cause of low back pain in the female athlete. Am J Sports Med. 2001; 29: 498-508. doi:10.1177/03635465010290042001

(9) **JOY EA, CAMPBELL D.** Stress fractures in the female athlete. Curr Sports Med Rep. 2005; 4: 323-328. doi:10.1097/01.CSMR.0000306294.72578.a8

(10) **KIEL J, KAISER K.** Stress Reaction and Fractures. In StatPearls. StatPearls Publishing. 2020.

(11) **LEROUX JL, DENAT B, THOMAS E, BLOTMAN F, BONNEL F.** Sacral insufficiency fractures presenting as acute low-back pain. Biomechanical aspects. Spine. 1993; 18: 2502-2506. doi:10.1097/00007632-199312000-00020

(12) **LIN JT, LANE JM.** Sacral stress fractures. J Womens Health (Larchmt). 2003; 12: 879-888. doi:10.1089/154099903770948104

(13) **LOMBARDO SJ, BENSON DW.** Stress fractures of the femur in runners. Am J Sports Med. 1982; 10: 219-227. doi:10.1177/036354658201000406

(14) **MICHELI LJ, CURTIS C.** Stress fractures in the spine and sacrum. Clin Sports Med. 2006; 25: 75-88. doi:10.1016/j.csm.2005.08.001

(15) **SCHIZAS C, THEUMANN N.** An unusual natural history of a L5-S1 spondylolisthesis presenting with a sacral insufficiency fracture. Eur Spine J. 2006; 15: 506-509. doi:10.1007/s00586-005-1011-6

(16) **SILVA RT, DE BORTOLI A, LAURINO CF, ABDALLA RJ, COHEN M.** Sacral stress fracture: an unusual cause of low back pain in an amateur tennis player. Br J Sports Med. 2006; 40: 460-461. doi:10.1136/bjsm.2005.023473

(17) **TENFORDE AS, BARRACK MT, NATTIV A, FREDERICSON M.** Parallels with the Female Athlete Triad in Male Athletes. Sports Med. 2016;46:171-182. doi:10.1007/s40279-015-0411-y

(18) **VAJAPEY S, MATIC G, HARTZ C, MILLER TL.** Sacral Stress Fractures: A Rare but Curable Cause of Back Pain in Athletes. Sports Health. 2019; 11: 446-452. doi:10.1177/1941738119854763

(19) **VOLPIN G, MILGROM C, GOLDSHER D, STEIN H.** Stress fractures of the sacrum following strenuous activity. Clin Orthop Relat Res. 1989; 243: 184-188. doi:10.1097/00003086-198906000-00028

(20) **YODER K, BARTSOKAS J, AVERELL K, MCBRIDE E, LONG C, COOK C.** Risk factors associated with sacral stress fractures: a systematic review. J Manual Manip Ther. 2015; 23: 84-92. doi:10.1179/2042618613Y.0000000055

(21) **ZAMAN FM, FREY M, SLIPMAN CW.** Sacral stress fractures. Curr Sports Med Rep. 2006; 5: 37-43. doi:10.1097/01.CSMR.0000306517.25172.68